

## ORTNER'S SYNDROME IN A PATIENT WITH GIANT LEFT ATRIUM

REVISTA ARGENTINA DE MEDICINA

ISSN 1515-3460

Buenos Aires

Perincek G, Avcı S, Kahraman F.

Ortner's syndrome in a patient  
with giant left atrium. *Rev Arg Med*  
2018;6[2]:111-114

### SÍNDROME DE ORTNER EN UN PACIENTE CON AURÍCULA IZQUIERDA GIGANTE

Gökhan Perincek,<sup>1</sup> Sema Avcı,<sup>2</sup> Ferdi Kahraman<sup>3</sup>

Recibido: 2 de febrero de 2018.  
Aceptado: 12 de marzo de 2018.

<sup>1</sup> MD. Departamento de Neumonología  
del Hospital Estatal Kars Harakani, Kars,  
Turquía.

<sup>2</sup> Departamento de Emergencias del  
Hospital Estatal Kars Harakani, Kars.

<sup>3</sup> Departamento de Cardiología del  
Hospital Estatal Kars Harakani, Kars.

#### ABSTRACT

Ortner's syndrome was first described in 1897 by Norbert Ortner, an Austrian physician, in a patient with hoarseness of voice due to a left recurrent laryngeal nerve paralysis, mitral stenosis and left atrial enlargement. Ortner's syndrome, commonly known as cardiovocal syndrome, is a clinical disease characterised by various underlying cardiopulmonary causes resulting in left recurrent laryngeal nerve palsy. Herein, we report Ortner's syndrome of a patient with giant left atrium and atrial fibrillation without mitral stenosis.

**KEY WORDS.** Pleural fluid, malignancy, FDG-PET/CT.

#### RESUMEN

El síndrome de Ortner fue descrito por primera vez en 1897 por el médico austriaco Norbert Ortner en un paciente con una disfonía debida a una parálisis del nervio laríngeo recurrente izquierdo, estenosis mitral y crecimiento auricular izquierdo. El síndrome de Ortner, comúnmente conocido como síndrome cardiovocal, es una enfermedad clínica caracterizada por varias causas cardiopulmonares de base que ocasionan una parálisis del nervio laríngeo recurrente izquierdo. Aquí presentamos el síndrome de Ortner de un paciente con una aurícula izquierda gigante y fibrilación auricular sin estenosis mitral.

**PALABRAS CLAVE.** Disnea, disfonía, aurícula izquierda.

Los autores manifiestan no poseer  
conflictos de intereses.

#### AUTOR PARA CORRESPONDENCIA

Sema Avcı. Kars Harakani Devlet Hastanesi.  
İsmail Aytemiz Bulvarı 36200 Merkez/  
Kars. Tel.: (+90530) 843-1363. Correo  
electrónico: dnlsema@gmail.com

## Introduction

Ortner's syndrome was first described in 1897 by Norbert Ortner, an Austrian physician, in a patient with hoarseness of voice due to left recurrent laryngeal nerve paralysis, mitral stenosis and left atrial enlargement (1). Ortner's syndrome, commonly known as cardiovocal syndrome, is a clinical disease characterised by various underlying cardiopulmonary causes resulting in left recurrent laryngeal nerve palsy (1,2). Mitral valve disorders such as stenosis, regurgitation, prolapse, aortic aneurysms; adult cardiovascular disorders such as left atrial enlargement, pulmonary hypertension, pulmonary embolism, congenital heart diseases; iatrogenic effects such as cardiac or thoracic surgery, defibrillation, atrial fibrillation ablation procedure are some of the cardiovascular conditions associated with Ortner's syndrome (3). Herein, we report Ortner's syndrome of a patient with giant left atrium and atrial fibrillation without mitral stenosis.

## Case report

A 67-year-old woman admitted to emergency department with long-standing history of dyspnoea and progressive vocal hoarseness of about six months. The chest radiography showed cardiomegaly and a computed tomography confirmed a massive dilated left atrium (Fig. 1). The electrocardiogram showed atrial fibrillation. The transthoracic echocardiography examination showed moderate-severe mitral regurgitation, mild to moderate tricuspid regurgitation and pulmonary arterial pressure was calculated 45 mmHg via tricuspid regurgitation velocity. Left ventricular ejection fraction was measured 57% according to Simpson's method. Maximum left atrial volume was found more than 1.5 fold higher than left ventricular end-diastolic volume and measured 147 ml. Atrial four chamber view and

moderate-severe mitral regurgitation left atrial volume (Figs. 2 and 3). A left vocal cord paralysis was confirmed on bronchoscopy (Figs. 4 and 5). A recurrent laryngeal nerve paralysis or paresis of cardiovascular origin known as Ortner's syndrome secondary to a massive dilated left atrium without mitral stenosis was diagnosed. Mitral valve replacement, left atrium minimization operation and radio-frequency ablation were recommended to her but the patient did not accept this treatment. Verbal informed consent was obtained from patient who participated in this publication.

## Discussion

Cardiovocal syndrome (Ortner's syndrome) is described by hoarseness due to cardiovascular diseases causing the compression of the left recurrent laryngeal nerve on its anatomical track, resulting in vocal cord palsy (2). In literature, mitral stenosis is the most common reason for this syndrome (2). In this case report, the patient showed a massive dilated left atrium without mitral stenosis but she had also atrial fibrillation and moderate-severe mitral regurgitation. Arifputera et al. reported the case of a 68-year-old man admitted for dysphagia, hoarseness and right vocal cord palsy. This case, where the patient had a giant left atrium which resulted from severe mitral regurgitation, was similar to our patient's (2). Plastiras et al. described the case of a 65-year-old woman with a history of hoarseness and exertional dyspnoea. She had an enlarged left atrium and mitral stenosis (3). Kishan et al. reported an 83-year-old woman with a history of hypertension, valvular heart disease, atrial fibrillation and cardiomegaly. She also had progressive hoarseness and intermittent dysphagia. Her echocardiography revealed severe dilated left and right atrium, moderate mitral regurgitation, severe tricuspid regurgitation and prolapse of the valves (4).

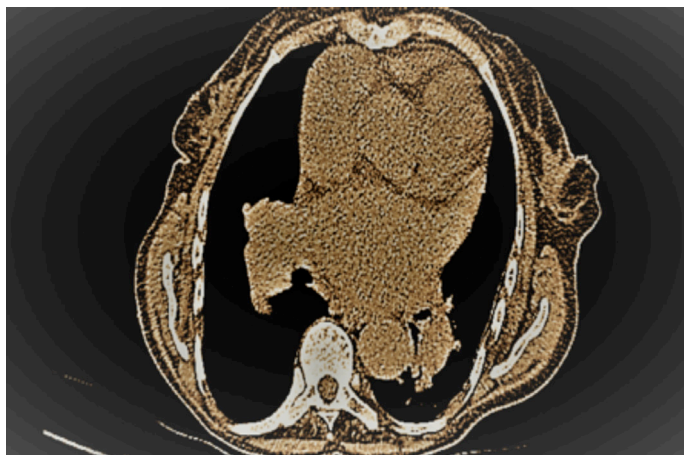


Figure 1.

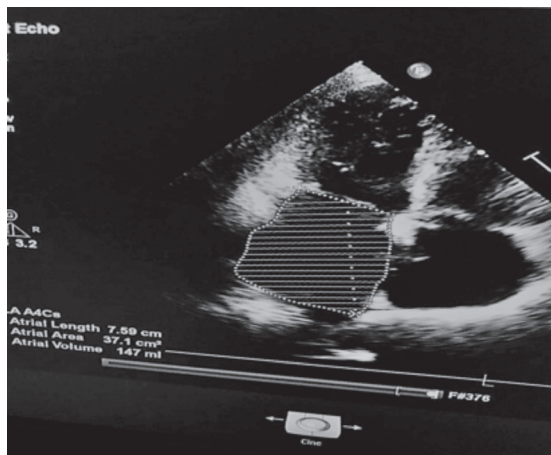


Figure 2.

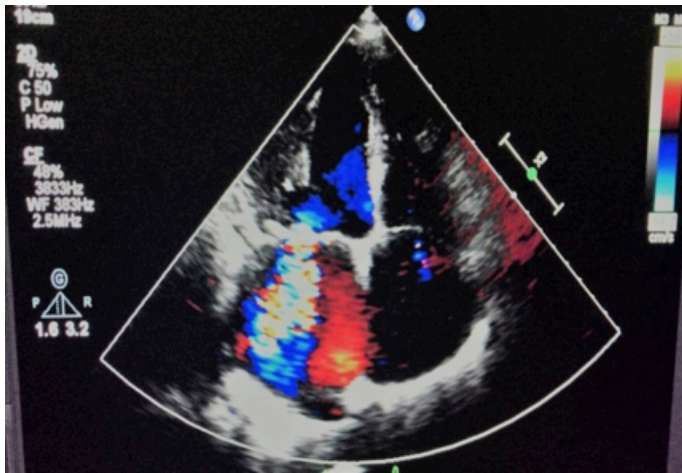


Figure 3.

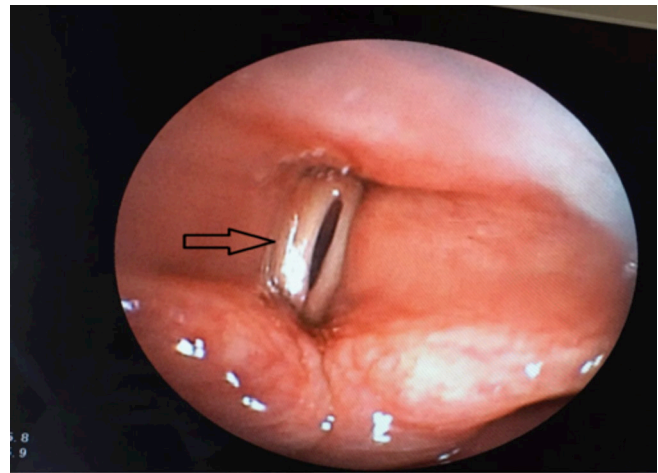


Figure 4.

Al Kindi et al. reported the case of a 72-year-old man with hypertension and a two-week history of left sided chest pain and hoarseness. A chest computed tomography angiography taken on the patient demonstrated a pseudoaneurysm in the lesser curvature of the distal aortic arch just opposite the origin of the left subclavian artery. The pseudoaneurysm was very close to the left recurrent laryngeal nerve and explained the patient's hoarseness (5). In literature, we can find various cardiovascular di-

seases associated with Ortner's syndrome. In this case, the reason of this syndrome was moderate-severe mitral regurgitation.

In conclusion, physicians should be careful about patients admitted to hospital with hoarseness and dyspnoea regarding cardiovascular diseases.

**Financial disclosure:** The author declared that for this case report he has received no financial support. [RAM](#)

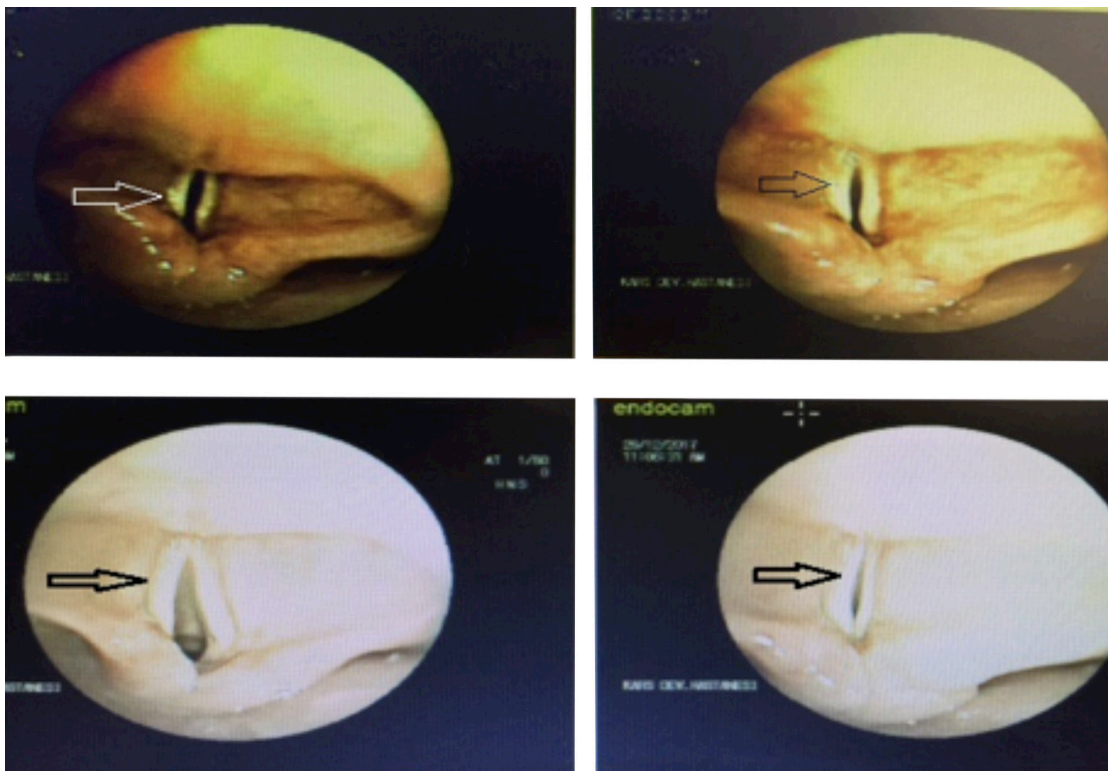


Figure 5.

## Referencias bibliográficas

1. Subramaniam V, Herle A, Mohammed N, et al. Ortner's syndrome: case series and literature review. *Braz J Otorhinolaryngol* 2011;77:559-62
2. Arifputera A, Loo G, Chang P, et al. An unusual case of dysphonia and dysphagia. *Singapore Med J* 2014;55:31-3
3. Plastiras SC, Pamboucas C, Zafiriou T, et al. Ortner's syndrome: a multifactorial cardiovocal syndrome. *Clin Cardiol* 2010;33:99-100
4. Kishan CV, Wongpraparut N, Adeleke K, et al. Ortner's syndrome in association with mitral valve prolapse. *Clin Cardiol* 2000;23:295-7
5. Al Kindi AH, Al Kindi FA, Al Abri QS, et al. Ortner's syndrome: Cardiovocal syndrome caused by aortic arch pseudoaneurysm. *J Saudi Heart Assoc* 2016;28:266-9